



Comparison of the localization of intrauterine adhesions in pregnant and infertile women

Gebe ve infertil kadınlarda intrauterin adezyonların lokalizasyonlarının karşılaştırılması

● Rukiye Ada Bender^{1,2}, ● Canan Özcan³, ● Bertan Akar⁴, ● Eray Çalışkan⁵

¹Biruni University School of Medicine, Department of Obstetrics and Gynecology, İstanbul, Turkey

²Medicana International Hospital, Clinic of Obstetrics and Gynecology, İstanbul, Turkey

³University of Health Sciences Turkey, Derince Training and Research Hospital, Clinic of Obstetrics and Gynecology, Kocaeli, Turkey

⁴Private Kocaeli Hospital, Clinic of Obstetrics and Gynecology, Kocaeli, Turkey

⁵Okan University Faculty of Medicine, Department of Obstetrics and Gynecology, İstanbul, Turkey

Abstract

Objective: Intrauterine adhesion (IUA) is the formation of band-shaped fibrotic tissues in the endometrial cavity due to uterine procedures. Most adhesions remain asymptomatic and do not affect fertility or pregnancy conditions. However, they may lead to infertility and pregnancy complications in some women. This study aimed to determine which localization and type of IUA may lead to infertility.

Materials and Methods: Seventy-six women with IUA were retrospectively scanned. Thirty-nine women with IUA with uterine factor-related infertility were included in the infertility group. Thirty-seven pregnant women, who had adhesions in the second-trimester ultrasonography and who had a live birth via cesarean section at term, were included in the pregnancy group. The localization of adhesions was determined as the fundus, corpus, isthmus, and cornu. Concerning the type of adhesion, the adhesions were classified as dense- and film-type adhesions.

Results: The infertility group was compared with the pregnancy group according to the type and localization of the adhesions. Fundal adhesions were significantly higher in the infertility group compared to the pregnancy group ($p<0.05$). The isthmic adhesions, however, were more common in the pregnancy group than in the infertility group ($p<0.05$). Dense-type adhesions were more common in the infertility group than in the pregnancy group ($p<0.05$).

Conclusion: According to the localization and types of adhesions, fundal and dense-type adhesions are among the features of uterine factor-related infertility. However, isthmus-located and film-type adhesions may not cause infertility.

Keywords: Intrauterine adhesion, Asherman's syndrome, infertility, hysteroscopy, pregnancy

Öz

Amaç: İnterauterin adezyon (İUA), uterin girişimlere bağlı olarak endometriyal kavitede bant şeklinde fibrotik dokuların oluşmasıdır. Çoğu adezyon, asemptomatik kalarak fertilitiyi ve gebelik koşullarını etkilemez. Ancak bazı kadınlarda infertiliteye ve olumsuz gebelik sonuçlarına neden olabilir. Bu çalışmanın amacı, hangi lokalizasyondaki ve hangi tipteki İUA'nın infertiliteye neden olabileceğini belirlemektir.

Gereç ve Yöntemler: İUA tespit edilen 76 kadına ait veriler, geriye dönük olarak tarandı. İnfertil kadınların grubuna, uterin faktöre bağlı infertilitesi olan 39 kadın dahil edildi. Gebe kadınların grubuna ise ikinci trimester ultrasonografide intaruterin adezyonları olan ve miadında sezaryen ile canlı doğum yapan 37 gebe kadın dahil edildi. Adezyonların lokalizasyonları; fundus, korpus, isthmus ve cornu olarak belirlendi. Adezyonlar tipine göre dens ve film tip olarak sınıflandırıldı.

PRECIS: To evaluate the effects of adhesion localization and types on fertility, we compared the adhesions of women who had a live birth at term with those of women who received infertility treatment.

Address for Correspondence/Yazışma Adresi: Rukiye Ada Bender MD,

Biruni University School of Medicine, Medicana International Hospital, Department of Obstetrics and Gynecology, İstanbul, Turkey

Phone: +90 505 910 44 99 **E-mail:** r.adabender@gmail.com **ORCID ID:** orcid.org/0000-0003-1210-8871

Received/Geliş Tarihi: 15.07.2022 **Accepted/Kabul Tarihi:** 16.08.2022

©Copyright 2022 by Turkish Society of Obstetrics and Gynecology

Turkish Journal of Obstetrics and Gynecology published by Galenos Publishing House.

Bulgular: Adezyonların tipi ve lokalizasyonuna göre infertil kadınların grubu, gebe kadınların grubu ile karşılaştırıldı. İnfertil kadınların grubunda, fundusda lokalize olan adezyonlar, gebe kadınların grubuna göre daha sık izlendi. İki grup aradaki fark istatistiksel olarak anlamlıydı ($p<0,05$). Ancak istmus yerleşimli adezyonlar, gebe kadınların grubunda infertil kadınların grubuna kıyasla daha sık olarak gözlemlendi ($p<0,05$). Dens tip adezyonlar ise, infertilite grubundaki kadınlarda, gebe gruptaki kadınlara göre daha sık gözlemlendi ($p<0,05$).

Sonuç: Lokalizasyon ve tipine göre, fundus yerleşimli ve dens tip adezyonlar, uterin faktöre bağlı infertilitenin önemli nedenleri arasındadır. Ancak istmus yerleşimli ve film tipteki adezyonlar ise infertiliteye neden olmayabilir.

Anahtar Kelimeler: İntrauterin adezyon, Asherman sendromu, infertilite, histeroskopi, gebelik

Introduction

Intrauterine adhesions (IUA) and Asherman's syndrome are terms that are often used interchangeably. IUA is identified as an increase in fibrotic tissue in the endometrial stromal and glandular alterations, which renders the functional and basal layers of the endometrium indistinguishable⁽¹⁾. Risk factors include the intrauterine processes that can damage the basalis layer, such as pregnancy, intrauterine procedures, infection or inflammation, and uterine compression suture⁽²⁾. Hysteroscopy is useful for diagnosis, classification, and treatment⁽³⁻⁵⁾. Adhesions spread are not limited to specific regions in the intrauterine cavity, instead, they may be observed not only in a specific localization of the intrauterine cavity such as the isthmus or fundus but also in the entire uterine cavity⁽⁶⁾.

Parameters such as grade, location, the severity of symptoms, appearance, prognosis, and postoperative outcome are used in the IUA classification^(4,7-10). The last classification in 2017 on IUA was developed based on the prognosis of the IUA, in collaboration with the European Society of Gynaecological Endoscopy (ESGE)^(3,9,10).

IUA presents an increased rate of infertility, poor implantation, and abortion^(11,12). The IUA-related infertility frequency is reported to be 43% and is distinguished by poor sperm motility and/or absence of implantation⁽¹³⁾. The possible complications in pregnant women with IUA are spontaneous abortion, intrauterine growth restriction, preterm delivery, placenta accreta, presentation abnormalities, or placenta previa⁽¹⁴⁻¹⁶⁾.

In this study, we determined the locations and type of IUA which are associated with uterine factor-related infertility.

Materials and Methods

This study was designed as a retrospective study and the patient data was retrieved from previous patient files from VM Medicalpark Kocaeli Private Hospital. The study was approved by the Kocaeli University Non-invasive Clinical Research Ethics Committee with the project number of 2017/305 and the reference number of KU GAKAEK 2017/15.7. All methods were carried out following the relevant guidelines and regulations.

Signed informed consent was obtained from all patients who were admitted to VM Medicalpark Kocaeli Hospital before the hysteroscopy and the routine ultrasonography (USG) for second-trimester abnormality screening.

The study was composed of 76 women with adhesions who met the study inclusion criteria. Thirty-nine women with a uterine

factor-based infertility history for at least one year were assigned to the infertility group. However, any IUA-unrelated infertility phenotypes were excluded from the study. Thirty-seven women suspected of adhesions in the second-trimester USG and who had a live birth via cesarean section at term were assigned to the pregnancy group of the study. This pregnancy group of patients had no recurrent pregnancy loss history or any fetal abnormalities. Amniotic fluid index, cervical length (>35 mm), and placentation was within the normal range according to the USG date (placenta accreta was not observed). The suspicions of adhesion in the second trimester USG of the women in this group were confirmed intraoperatively during cesarean section. The IUA in the infertility group was diagnosed by a filling defect on hysterosalpingography and hysteroscopy. The adhesion in the pregnancy group was incidentally diagnosed during the second-trimester USG screening and confirmed intraoperatively during cesarean section for the presence of any abnormality. The IUA of the women were evaluated by a single specialist with a similar procedure, using the same hysteroscope and USG instrument. In the second trimester USG, adhesions were previously defined by the same specialist as "Sheet on string"⁽¹⁷⁾ (Figure 1).

The IUA is classified into four distinct groups according to their localization isthmus, corpus, fundus, and corns. According to their structures, synechiae are classified as film or thick adhesions.

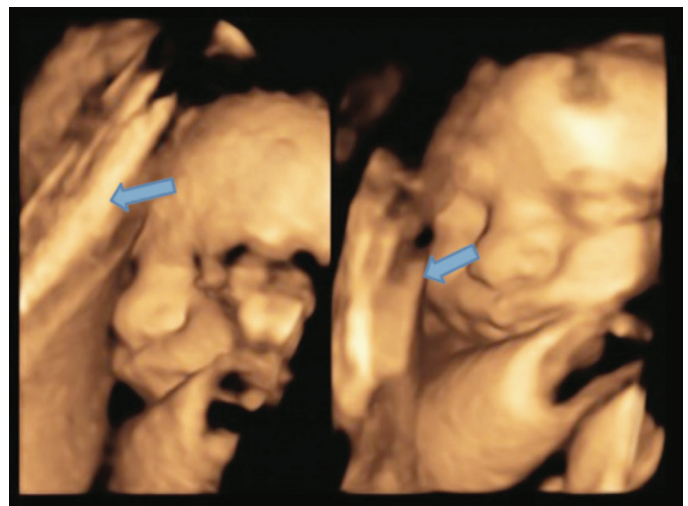


Figure 1. Intrauterine adhesion demonstrated using 4D ultrasonography; "sheet on a string" appearance of the pregnancy group⁽¹⁷⁾

Statistical Analyses

Retrospective data were statistically evaluated with the Statistical Package for the Social Sciences program (version 20). Data were collected as mean and \pm standard deviation of quantitative variables. Frequency and percentage values were used to summarize the qualitative variables. The odds ratio and 95% confidence interval were calculated for each result. The group comparisons were performed using the chi-square test and Student's t-test for qualitative variables. A p-value of <0.05 was considered statistically significant.

Results

The women with IUA were divided into 2 groups according to the imaging methods of the adhesions. The diagnosis of adhesions in the infertility group was made by hysteroscopic procedure and the diagnosis of adhesions in the pregnancy group was made by the second trimester USG. For both groups of patients, we recorded age, body mass index, number of gravidities, number of parity, number of miscarriages, number of menstrual regulation, presence of prior infertility treatment, and prior cesarean section (Table 1). Statistically, a significant difference was observed among all the whole demographic data except for the body mass index and number of gravidity.

Figures 2 and 3 depict the localizations and types of adhesions in both groups. The dense-type and fundal adhesions of the infertility group and the film-type and isthmic adhesions of the pregnancy group are shown in the figures.

The results of the study are given in Table 2. The dense-type adhesions were found to be more common than the film-type adhesions in the infertility group ($p=0.006$). In the pregnancy group, however, the film-type adhesions were more frequent than dense-type adhesions ($p=0.006$). Adhesions were also evaluated in terms of their localization. Among the adhesions

in the infertility group, those localized in the fundus were more common than those localized in the isthmus, corns, and corpus [$n=27$ (69.2%)]. Besides, the adhesions of the pregnancy group localized in the isthmus were observed more frequently than adhesions localized in the fundus, corns, and corpus [$n=20$ (54.1%)].

The types and localizations of the adhesions were compared among the groups. According to our findings, dense-type adhesions were observed to be more frequent in the infertility group compared with the pregnancy group ($p<0.05$). As the frequency of film-type adhesions was compared, film-type adhesions were observed to be more common in the pregnancy group than in the infertility group ($p<0.05$). As the localization

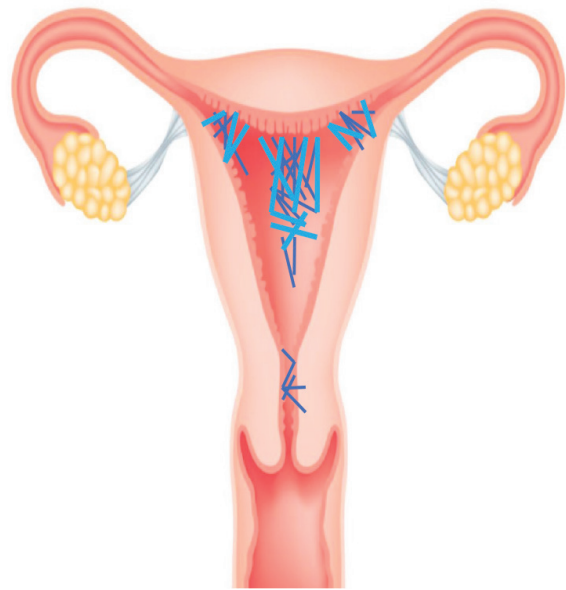


Figure 2. Intrauterine adhesions of the infertility group

Table 1. Baseline characteristics of the participants

Characteristic	Infertility group (n=39)	Pregnancy group (n=37)	p-value
Age (year) mean \pm SD [§]	30.4 \pm 3.2	27.8 \pm 4.3	0.003
BMI [§] (kg/m ²) mean \pm SD	26.1 \pm 4.9	25.2 \pm 5.3	0.39
Number of gravidity mean \pm SD	2.79 \pm 1.1	2.89 \pm 0.7	0.66
Number of parity mean \pm SD	0.33 \pm 0.57	0.70 \pm 0.46	0.003
Number of miscarriages mean \pm SD	1.94 \pm 1.2	0.78 \pm 0.7	<0.001
Number of menstrual regulation mean \pm SD	0.1 \pm 0.3	0.4 \pm 0.5	0.002
Prior infertility treatment	28 (71%)	5 (13%)	<0.001
Prior cesarean section	6 (15%)	21 (56%)	<0.001

SD[§]: Standart deviation, BMI[§]: Body mass index, a p-value of <0.05 was considered statistically significant

of the adhesions was evaluated, fundal localization was found to be more common in the infertility group than the pregnancy group ($p=0.001$); and the prevalence of isthmic and cornual localizations was higher in the pregnancy group compared to the infertility group [Table 2, ($p<0.05$)].

Discussion

The IUA can emerge with noticeable symptoms, asymptomatic symptoms, or mainly with the complaint of infertility/subfertility, which is the most prevalent presentation of IUA^(18,19).

The hysteroscopy is the gold standard diagnostic method of IUA^(3,20). The last ESGE classification in 2015 was based on the prognosis of the IUA^(9,10,21). However, there is no study in the literature reporting the relationship between infertility and IUA localization^(3,10,22,23). Tubal and isthmus but not fundus and corpus-localized adhesions are included in calcifications^(3,10).

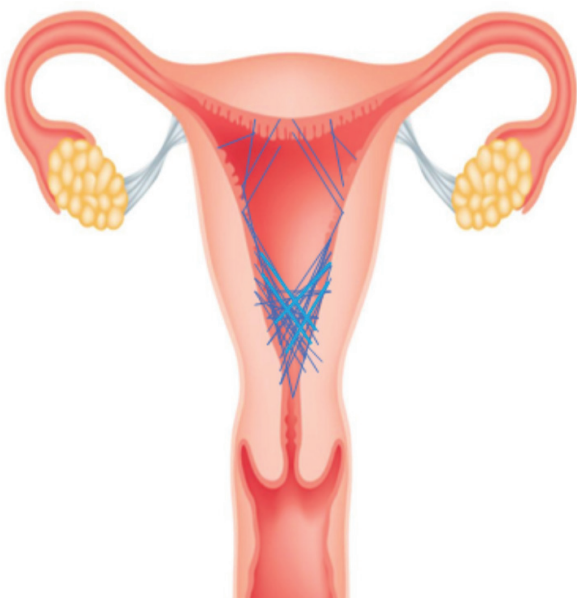


Figure 3. Intrauterine adhesions of the pregnancy group

As we have hypothesized that the type and localization of adhesions may affect uterine factor-related infertility, we retrospectively compared the results of hysteroscopy for diagnosis and treatment of women with uterine factor-related infertility and the results of the second-trimester USG screening of pregnant women with IUA for the presence of any abnormality.

In the infertility group, any IUA-unrelated infertility phenotypes were excluded from the study to evaluate the net effects of adhesions. Women with adverse pregnancy outcomes (such as fetal anomaly, placenta accreta, and preterm birth) were excluded from the study in the pregnancy group for similar reasons. The fact that hysteroscopy procedures and second-trimester USG were conducted by the same expert is one of the major features that helped standardize the outcomes of this study.

We observed that the adhesions in the fundal localization were more frequent in the infertility group than in the pregnancy group. This finding supports the idea that the fundus-localized adhesions have a negative impact on fertility. In a survey conducted by Feng et al.⁽¹⁴⁾ in 1999, the authors concluded that if the overall area of the endometrium changes by the presence of increased adhesions, fetal improvement would be negatively affected due to decreased vascularization. In parallel with these findings, we found that dense-type adhesions were more common in the infertility group. According to this outcome, when the area in the endometrium influenced by adhesions increases, fetal improvement is negatively impacted due to decreased vascularization. Fundal adhesions, probably, are considered as infertility leading factor due to restraining the implantation and growth of the fetus⁽¹⁵⁾. In a previous essential study, isthmic adhesions were concluded to have roles in infertility by inhibiting sperm motility from fundus to fallopian tubes⁽⁶⁾. However, there is no study in the literature validating the results of this study.

In this study, the presence of amniotic fluid in the second trimester USG enabled us to easily detect adhesions like saline in

Table 2. The results of hysteroscopic procedure in the infertility group and the results of second trimester ultrasonography in the pregnancy group

	Infertility group	Pregnancy group	p-value
Type of adhesions			
Rate of film adhesions	23 (59%)	33 (89.2%)	0.006
Rate of dense adhesions	16 (41%)	4 (10.8%)	0.006
Ratios of adhesions according to their localization			
Isthmus	3 (7.7%)	20 (54.1%)	0.001
Fundus	27 (69.2%)	1 (2.7%)	0.001
Corpus	7 (17.9%)	4 (10.8%)	0.577
Cornu	2 (5.1%)	12 (32.4%)	0.002

SD: Standard deviation, a p-value of <0.05 was considered statistically significant

hysterosonography. In these women, through second-trimester USG screening, isthmic and cornual adhesions were observed more frequently than in other localizations. Considering the healthy pregnancies of these women, which resulted in term and live birth, we conclude that the isthmic and cornual adhesions may not adversely affect the formation and continuation of pregnancy. According to the IUA's most recent classifications, no studies define adhesions as film or dense.

When pregnancy coexists the presence of IUA; spontaneous abortion, intrauterine growth restriction, premature labor, placenta accreta, or placenta previa, and presentation abnormalities are to be expected⁽¹⁴⁻¹⁶⁾.

There is not enough literature data comparing expectant management with the surgical approach, but surgery is indicated in symptomatic patients⁽³⁾. In a review of postoperatively evaluated infertile 800 patients, 60% pregnancy rate and 38.8% live birth rates were reported, whereas the live birth rate in a randomized controlled trial was 60-70%^(6,13). However, complications such as new adhesion formation due to destruction in the endometrium, uterine perforation, visceral damage if uterine perforation occurs, complications related to anesthesia, fluid overload (hyponatremia) due to distending media used, and gas embolism can also be observed after hysteroscopy⁽³⁾.

Study Limitations

The limitations of the authors' study are that pregnancy outcomes after hysteroscopy were excluded from the infertility group and adhesions were not evaluated with hysteroscopy in either group. Hysteroscopy is the gold standard method for evaluating adhesions. Therefore, in future studies to determine the effects of adhesions on fertility, adhesions in randomly selected women should be evaluated by hysteroscopy and long-term fertility results should be included.

Conclusion

At this point, surgical treatment for the right indication gains importance. However, there is no data in the literature revealing the relationship between adhesion type & localization with the prognosis to determine the correct indication. This study shows that the effects of localization and types of adhesions on prognosis may be important in evaluating the current classification systems and will be important in determining the correct indications of the surgical approach. However, there is a need for more randomized controlled studies with larger numbers of patients to evaluate the effects of localization and types of adhesions on uterine factor-related infertility.

Ethics

Ethics Committee Approval: The study was approved by the Kocaeli University Non-invasive Clinical Research Ethics Committee with the project number of 2017/305 and the reference number of KU GAKAEK 2017/15.7.

Informed Consent: Signed informed consent was obtained from all patients.

Peer-review: Internally peer-reviewed.

Authorship Contributions

Surgical and Medical Practices: E.Ç., Concept: R.A.B., C.Ö., E.Ç., Design: R.A.B., C.Ö., E.Ç., Data Collection or Processing: R.A.B., C.Ö., B.A., E.Ç., Analysis or Interpretation: R.A.B., C.Ö., B.A., E.Ç., Literature Search: R.A.B., Writing: R.A.B.

Conflict of Interest: No conflict of interest was declared by the authors.

Financial Disclosure: The authors declared that this study received no financial support.

References

1. Foix A, Bruno RO, Davison T, Lema B. The pathology of postcurettage intrauterine adhesions. *Am J Obstet Gynecol* 1966;96:1027-33.
2. Salazar CA, Isaacson K, Morris S. A comprehensive review of Asherman's syndrome: causes, symptoms and treatment options. *Curr Opin Obstet Gynecol* 2017;29:249-56.
3. AAGL Elevating Gynecologic Surgery. AAGL Practice Report: Practice Guidelines on Intrauterine Adhesions Developed in Collaboration With the European Society of Gynaecological Endoscopy (ESGE). *J Minim Invasive Gynecol* 2017;24:695-705.
4. March CM, Israel R, March AD. Hysteroscopic management of intrauterine adhesions. *Am J Obstet Gynecol* 1978;130:653-7.
5. Kodaman PH, Arici A. Intra-uterine adhesions and fertility outcome: how to optimize success? *Curr Opin Obstet Gynecol* 2007;19:207-14.
6. Deans R, Abbott J. Review of intrauterine adhesions. *J Minim Invasive Gynecol* 2010;17:555-69.
7. Hamou J, Salat-Baroux J, Siegler AM. Diagnosis and treatment of intrauterine adhesions by microhysteroscopy. *Fertil Steril* 1983;39:321-6.
8. Valle RF, Sciarra JJ. Intrauterine adhesions: hysteroscopic diagnosis, classification, treatment, and reproductive outcome. *Am J Obstet Gynecol* 1988;158:1459-70.
9. The American Fertility Society classifications of adnexal adhesions, distal tubal occlusion, tubal occlusion secondary to tubal ligation, tubal pregnancies, müllerian anomalies and intrauterine adhesions. *Fertil Steril* 1988;49:944-55.
10. Nasr AL, Al-Inany HG, Thabet SM, Aboulghar M. A clinicohysteroscopic scoring system of intrauterine adhesions. *Gynecol Obstet Invest* 2000;50:178-81.
11. Asherman JG. Amenorrhoea traumatica (atretica). *J Obstet Gynaecol Br Emp* 1948;55:23-30.
12. Asherman JG. Traumatic intra-uterine adhesions. *J Obstet Gynaecol Br Emp* 1950;57:892-6.
13. Schenker JG, Margalioth EJ. Intrauterine adhesions: an updated appraisal. *Fertil Steril* 1982;37:593-610.
14. Feng ZC, Yang B, Shao J, Liu S. Diagnostic and therapeutic hysteroscopy for traumatic intrauterine adhesions after induced abortions: clinical analysis of 365 cases. *Gynaecological Endoscopy* 1999;8:95-8.
15. Chen L, Zhang H, Wang Q, Xie F, Gao S, Song Y, et al. Reproductive Outcomes in Patients With Intrauterine Adhesions Following Hysteroscopic Adhesiolysis: Experience From the Largest Women's Hospital in China. *J Minim Invasive Gynecol* 2017;24:299-304.

16. Engelbrechtsen L, Langhoff-Roos J, Kjer JJ, Istre O. Placenta accreta: adherent placenta due to Asherman syndrome. *Clin Case Rep* 2015;3:175-8.
17. Caliskan E, Bender RA, Aslanca R. Diagnostic sign of intra uterine extra amniotic adhesions with 4D ultrasonography: Sheet on string. *Turk J Obstet Gynecol* 2018;15:133-4.
18. Schenker JG. Etiology of and therapeutic approach to synechia uteri. *Eur J Obstet Gynecol Reprod Biol* 1996;65:109-13.
19. Taylor PJ, Cumming DC, Hill PJ. Significance of intrauterine adhesions detected hysteroscopically in eumenorrhic infertile women and role of antecedent curettage in their formation. *Am J Obstet Gynecol* 1981;139:239-42.
20. Magos A. Hysteroscopic treatment of Asherman's syndrome. *Reprod Biomed Online* 2002;4(Suppl 3):46-51.
21. Wamsteker K, DeBlok S. Diagnostic hysteroscopy: Technique and documentation. In: Sutton, C. and Diamond, M., Eds., *Endoscopic surgery for gynaecologists*, Saunders, London; 1993. p. 263-76.
22. Donnez J, Nisolle M. Hysteroscopic adhesiolysis of intrauterine adhesions (Asherman syndrome) In: Donnez J, editor. *Atlas of Laser Operative Laparoscopy and Hysteroscopy*. London, UK: Parthenon Publishing Group; 1994. p. 305-22.
23. Carp HJ, Ben-Shlomo I, Mashiach S. What is the minimal uterine cavity needed for a normal pregnancy? An extreme case of Asherman syndrome. *Fertil Steril* 1992;58:419-21.