



Should isolated aberrant right subclavian artery be ignored in the antenatal period? A management dilemma

Antenatal dönemde izole aberran sağ subklavyen arter gözardı edilmeli mi? Bir yönetim ikilemi

Mustafa Behram¹, Sema Süzen Çaypınar¹, Süleyman Cemil Oğlak², Salim Sezer¹,
Aytul Çorbacıoğlu Esmer³

¹University of Health Sciences Turkey, Kanuni Sultan Süleyman Training and Research Hospital, Clinic of Perinatology, İstanbul, Turkey

²University of Health Sciences Turkey, Gazi Yaşargil Training and Research Hospital, Clinic of Obstetrics and Gynecology, Diyarbakır, Turkey

³Biruni University Faculty of Medicine, Department of Perinatology, İstanbul, Turkey

Abstract

Objective: To investigate the frequency and types of chromosomal abnormalities in fetuses with the aberrant right subclavian artery (ARSA) and to evaluate its association with other ultrasonographic findings.

Materials and Methods: In all, 11,666 fetal anatomic surveys were performed between March 2014 and March 2020. The cases diagnosed as ARSA were examined. Accompanying ultrasound findings and chromosomal abnormalities were collected.

Results: ARSA was detected in 140 fetuses (1.2%). The ARSA appeared isolated in 47.1% (66/140) of cases and the remaining 52.9% (74/140) of cases were associated with cardiac or extracardiac malformations and soft markers. Chromosomal abnormalities were detected in 17.8% (25/140) of all cases. Trisomy 21 was the most common chromosomal anomaly with a prevalence of 11.4% (16/140). The corresponding rate was 3% (2/66) and 18.9% (14/74) for isolated and non-isolated ARSA, respectively. DiGeorge syndrome was detected in 3% (n=2) and Turner syndrome was in 3% (n=2) of the isolated group. ARSA was not an isolated finding in any of the 4 fetuses with trisomy 18.

Conclusion: Isolated ARSA may be the only antenatal predictor of trisomy 21 or other chromosomal anomalies, including DiGeorge or Turner syndrome. Hence, visualization of the right subclavian artery should be a part of the fetal anatomic survey and genetic analysis should be recommended even in the absence of associated findings.

Keywords: Aberrant right subclavian artery, DiGeorge syndrome, Down syndrome, Turner syndrome, prenatal diagnosis

Öz

Amaç: Aberran sağ subklavyen arteri (ASSA) olan fetüslerde kromozomal anomalilerin sıklığını ve tiplerini belirlemek ve diğer sonografik bulgularla ilişkisini değerlendirmektir.

Gereç ve Yöntemler: Mart 2014 ile Mart 2020 tarihleri arasında toplam 11,666 fetal anatomik inceleme yapıldı. ASSA tanısı konulan olgular incelendi. Eşlik edilen ultrason bulguları ve kromozom anormallikleri toplandı.

Bulgular: Yüz kırk fetüste (%1,2) ASSA tespit edildi. ASSA, olguların %47,1'inde (66/140) izole olarak görüldü ve olguların geri kalan %52,9'u (74/140) kardiyak anomaliler, ekstrakardiyak malformasyonlar veya minör belirteçler ile ilişkili bulundu. Tüm olguların %17,8'inde (25/140) kromozom anormallikleri tespit edildi. Trizomi 21, %11,4 (16/140) prevalansı ile en sık görülen kromozomal anomaliydi. İzole ve izole olmayan ASSA için karşılık gelen oranlar sırasıyla %3 (2/66) ve %18,9 (14/74) idi. İzole grupta %3 (n=2) DiGeorge sendromu ve %3 (n=2) Turner sendromu da saptandı. ASSA, trizomi 18'i olan 4 olgunun hiçbirinde izole bir bulgu değildi.

Sonuç: İzole ASSA, trizomi 21'in veya DiGeorge veya Turner sendromu dahil diğer kromozomal anomalilerin tek antenatal prediktörü olabilir. Bu nedenle, sağ subklavyen arterin görselleştirilmesi fetal anatomik incelemenin bir parçası olmalı ve ilişkili bulguların yokluğunda bile genetik analiz önerilmelidir.

Anahtar Kelimeler: Aberran sağ subklavyen arter, DiGeorge sendromu, Down sendromu, Turner sendromu, prenatal tanı

PRECIS: Aberrant right subclavian artery (ARSA) may be the only antenatal ultrasound finding of trisomy 21, DiGeorge and Turner syndromes in the second or third trimester.

Address for Correspondence/Yazışma Adresi: Süleyman Cemil Oğlak MD, University of Health Sciences Turkey, Gazi Yaşargil Training and Research Hospital, Clinic of Obstetrics and Gynecology, Diyarbakır, Turkey

Phone: +90 506 402 11 57 **E-mail:** sampson_21@hotmail.com **ORCID ID:** orcid.org/0000-0001-7634-3008

Received/Geliş Tarihi: 12.01.2021 **Accepted/Kabul Tarihi:** 22.03.2021

Introduction

Aberrant right subclavian artery (ARSA) is the most common congenital abnormality of the aortic arch with a frequency of 1-1.5% in an apparently healthy population⁽¹⁻³⁾. In normal anatomy, the right subclavian artery originates from the brachiocephalic trunk, one of the three main branches of the aortic arch. In contrast, ARSA is an anatomic variation in which the right subclavian artery originates from the aortic arch directly as an additional artery, usually distal to the left subclavian artery. It must course from the left side to right of the midline, usually behind the trachea and esophagus⁽⁴⁾. Typically, ARSA is a benign finding and usually asymptomatic. However, ARSA occasionally causes dysphagia or dyspnea in the pediatric population^(5,6).

In recent years, ARSA has been associated with chromosomal abnormalities and has gained notoriety. The first report demonstrating the ARSA and relationship with Down syndrome was published in 2005⁽⁷⁾, and thereafter a few other studies emphasized the importance of this benign variant, even if isolated and showing the presence of trisomy 21 in isolated cases^(4,5,8,9). Most trials revealed that additional cardiac or extracardiac abnormalities accompanied ARSA in fetuses with trisomy 21^(10,11). Moreover, ARSA has been reported with other less common genetic disorders such as 22q11.2 deletion or Turner syndrome^(12,13).

This study aimed to determine the frequency and types of chromosomal anomalies among fetuses with ARSA and to evaluate the additional sonographic abnormal findings associated with ARSA in a large study group.

Materials and Methods

This study was approved by our institutional review board. A waiver of informed consent was obtained owing to the study's retrospective nature. We performed a retrospective review of fetuses antenatally diagnosed as having ARSA between March 2014 and March 2020 in the perinatology unit of our hospital, which is a reference center in our city.

Fetuses with ARSA were identified from hospital databases and hospital charts. Both low and high-risk patients in the second and third trimesters were included in the study. We collected data by focusing on antenatal screening tests, fetal anatomy ultrasound scans, fetal echocardiograms, and reports of genetic analysis, and reviewed all neonatal and pediatric records. Examinations were performed using high-resolution equipment (Voluson E6 expert, GE Healthcare, Milwaukee, WI, USA) by perinatologists who were experts in fetal anatomic surveys and echocardiography. Color Doppler ultrasonography was used for visualizing the right subclavian artery as previously described by Chaoui et al.⁽⁷⁾ (Figure 1). ARSA was detected as an additional vessel arising from the junction of the aortic arch and ductus arteriosus, and passing behind the trachea to the opposite side. In all patients with a diagnosis of ARSA, detailed fetal anatomical scanning and echocardiography were

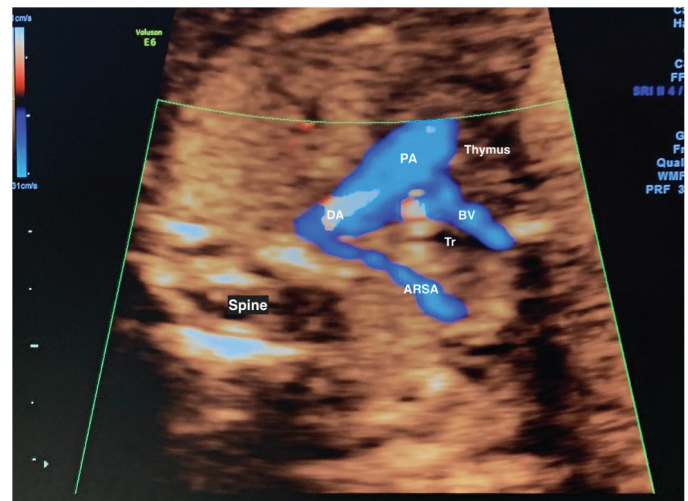


Figure 1. Transabdominal color Doppler axial image shows an aberrant right subclavian artery. ARSA arising directly from the junction of the aortic arch and ductus arteriosus and passing behind the trachea to the opposite side

ARSA: Aberrant right subclavian artery, DA: Ductus arteriosus, PA: Pulmonary artery, BV: Brachiocephalic vein, Tr: Trachea

performed to look for additional abnormal ultrasound findings. The cases of ARSA were divided into two groups as isolated if ARSA was the only antenatal sonographic finding in the 2nd or 3rd trimester, and non-isolated, those with concomitant sonographic findings including cardiac or extracardiac abnormalities and soft markers. Nuchal fold thickness, aplasia or hypoplasia of nasal bone, echogenic intracardiac focus, hyperechogenic bowel, mild pyelectasis, and short femur or humerus (<5th percentile) were accepted as soft markers. Extracardiac abnormalities referred to all abnormal sonographic findings including fetal growth restriction, except for cardiac anomalies. Fetal biometric measurements were made according to Hadlock nomograms and estimated fetal weight (EFW) was calculated with the Hadlock formula. Those with abdominal circumference (AC)/EFW <3rd percentile or absent-reverse end-diastolic flow in the umbilical artery or AC/EFW <10th percentile combined with a pulsatility index >95th percentile in either the umbilical or uterine artery were considered to have an intrauterine growth restriction⁽¹⁴⁾.

Prenatal invasive diagnostic tests for karyotype analysis including fluorescence *in situ* hybridization (FISH) analysis were proposed in each case of ARSA. Blood samples were taken in the postnatal period for genetic analysis from infants whose parents did not accept the antenatal invasive test. The presence of ARSA in all cases was confirmed through postnatal echocardiography or computed tomography. Cases without prenatal or postnatal genetic diagnostic tests and postnatal confirmation were excluded from the study.

Statistical Analysis

We used the IBM SPSS 21.0 for Windows (SPSS Inc., Chicago, IL, USA) statistical package for the statistical evaluation of our

research data. The measured variables are presented as mean \pm standard deviation and categorical variables are presented as numbers and percentages (%). The Kolmogorov-Smirnov test was used to determine whether the numerical data matched normal distribution. The Student's t-test and Mann-Whitney U test were used to compare the groups. A p-value <0.05 was considered to be statistically significant.

Results

The anatomic screening data of a total of 11,666 fetuses were assessed and ARSA was identified in 140 fetuses over the study period. The antenatal prevalence of ARSA in our study was 1.2%. ARSA was diagnosed in the second trimester in 92/140 (65.7%) patients and the third trimester in 48/140 (34.3%) patients. At the time of diagnosis, the mean gestational age was 22.3 ± 4.5 weeks, and the mean maternal age was 31.2 ± 5.5 years. ARSA appeared isolated in 47.1% (66/140) of cases and it was found to be associated with a cardiac or extracardiac abnormal finding and/or a soft marker in the remaining 52.9% (74/140). Cardiac anomalies, extracardiac malformations, and soft markers were detected in 21.6% (16/74), 51.3% (38/74), and 40.5% (30/74) of cases, respectively. Some of the fetuses had more than one type of abnormal finding (e.g. cardiac and/or extracardiac anomalies and soft markers in the same fetus). Antenatal screening tests were performed in 97/140 (69.2%) patients, including 57 first-trimester screening, 18 triple tests, and 22 quadruple tests. In 24 of these patients, cell-free fetal DNA screening was also performed.

Prenatal invasive diagnostic tests and karyotype analysis using FISH were performed in 88/140 cases. Sampling was performed by amniocentesis in 65/88 cases, cordocentesis in 13/88, and chorionic villus biopsy in the remaining 10/88 cases. Postnatal genetic examinations were performed in the remaining 52/140 cases. Chromosomal abnormalities were detected in 17.8% (25/140) of all cases. The corresponding rate was 9% (6/66) and 25.6% (19/74) for isolated and non-isolated ARSA, respectively. Trisomy 21 was the most common chromosomal anomaly with a prevalence of 11.4% (16/140). The corresponding rate was 3% (2/66) and 18.9% (14/74) for isolated and non-isolated ARSA, respectively. The other chromosomal anomalies were trisomy 18, 22q11.2 deletion (DiGeorge syndrome), and Turner syndrome. The distribution of chromosomal abnormalities in fetuses with ARSA is shown in Table 1.

The list of sonographic findings observed in fetuses with non-isolated ARSA is shown in Table 2. The most common cardiac anomaly associated with ARSA was a ventricular septal defect (n=6, 4.2%), and the most common extracardiac finding and soft marker was fetal growth restriction (n=8, 5.7%) and echogenic cardiac focus (n=12, 8.5%), respectively.

Details of cases with a chromosomal abnormality are presented in Table 3.

Table 1. Distribution of chromosomal abnormalities in fetuses with ARSA by gestational age and maternal age

	Isolated (n=66)	Non-isolated (n=74)	Total (n=140)
Mean GA at diagnosis, weeks (SD)	21.6 \pm 4.2	23.4 \pm 2.8	22.3 \pm 4.5
Mean maternal age, years (SD)	32.3 \pm 5.3	31.4 \pm 5.1	31.2 \pm 5.5
Maternal age \geq 35	21(31.8)	20 (27)	41(29.2)
Trisomy 21 *	2 (3)	14 (18.9)	16 (11.4)
DiGeorge syndrome	2 (3)	1 (1.3)	3 (2.1)
Turner syndrome	2 (3)	None	2 (1.4)
Trisomy 18	None	4 (5.4)	4 (2.8)
All anomalies **	6 (9)	19 (25.6)	25 (17.8)

*p=0.024, ** p=0.003, p>0.05 for all other parameters. Percentage values are shown in parentheses, Student's t-test, Mann-Whitney U test, ARSA: Aberrant right subclavian artery

Discussion

Previous studies revealed the prevalence rate of ARSA ranging between 0.4% and 2% among the general population^(3,10,15). Our study is one of the largest on ARSA in the literature and we identified 140 cases of ARSA with a prevalence rate of 1.2%.

During the last decade, many studies in the literature investigated isolated or non-isolated ARSA with additional abnormalities and its relationship with chromosomal anomalies⁽⁵⁾. Esmer et al.⁽⁵⁾ first reported 14 trisomy-21 cases between 18 and 33 weeks of gestation and ARSA was detected in 5/14 (35.7%). In one of these cases, ARSA was the only abnormal ultrasound finding. Gul et al.⁽⁹⁾ also reported 17 cases of ARSA and only one case was diagnosed with trisomy 21. ARSA was the only ultrasound finding in this fetus. Similarly, Borenstein et al.⁽³⁾ published a case series of 8 fetuses with Down syndrome with ARSA, and in one of them, the ARSA was isolated. Zalel et al.⁽¹⁶⁾ reported three cases of ARSA in eight fetuses with Down syndrome, but none of these cases was isolated. In another large study, Svirsky et al.⁽¹⁷⁾ found a high prevalence of trisomy 21 in fetuses with ARSA, but none in the isolated group.

In our study, we demonstrated 16 cases of trisomy-21 in fetuses with ARSA and two were in the isolated group. Paladini et al.⁽¹⁸⁾ reported a case series of 27 fetuses with ARSA and Down syndrome and ARSA was an isolated sonographic finding in eight (29.6%). In this study, the authors suggested that in addition to nasal bone aplasia/hypoplasia and nuchal fold thickness, ARSA should be one of the most important ultrasound markers of Down syndrome in the 2nd trimester.

In 2006, Chaoui et al.⁽¹⁹⁾ reported the prevalence of ARSA in fetuses with major chromosomal abnormalities as 34% (16/47). Ratios were found as 28.5% (4/14), 55.5% (5/9), and 50% (2/4) in trisomy 21, trisomy 18, and trisomy 13, respectively. Also, ARSA was detected at a rate of 43% (3/7) in Turner syndrome and 14% (1/7) in DiGeorge syndrome. ARSA was not the only ultrasound finding in any of these cases.

Table 2. Sonographic findings of fetuses with non-isolated ARSA in second or third trimester (some of the fetuses had more than one abnormal finding)

Cardiac anomalies	n (%)	Extracardiac findings	n (%)	Soft markers	n (%)
Ventricular septal defect	6 (4.2)	Fetal growth restriction	8 (5.7)	Echogenic Intracardiac focus	12(8.5)
Coarctation of aorta	3 (2.1)	Ventriculomegaly	7 (5)	Mild pyelectasis	8 (5.7)
PLSVC	3 (2.1)	Single umbilical artery	5 (3.5)	Hyperechoic bowel	7 (5)
AVSD	2 (1.4)	Corpus callosum agenesis	3 (2.1)		
Tetralogy of fallot	2 (1.4)	Omphalocele	2 (1.4)	Nasal bone hypo/aplasia	6 (4.2)
DORV	2 (1.4)	Club foot	2 (1.4)	Short femur/ humerus	6 (4.2)
Interrupted aortic arch	1 (0.7)	Micrognathia	2 (1.4)	Thick nuchal fold	1 (0.7)
Aortic stenosis	1 (0.7)	PRUV	2 (1.4)		
		Cleft lip palate	2 (1.4)		
		2 (1.4)			
Hand deformities		2 (1.4)			
Polyhydramnios		1 (0.7)			
Holoprosencephaly		1 (0.7)			
Dandy-Walker malformation		1 (0.7)			
Thymic hypoplasia		1 (0.7)			
Hyperechoic kidney		1 (0.7)			
Cystic hygroma		1 (0.7)			

PLSVC: Persistent left superior vena cava, AVSD: Atrioventricular septal defect, DORV: Double outlet right ventricle, PRUV: Persistent right umbilical vein, ARSA: Aberrant right subclavian artery

Table 3. Details of ARSA cases with a chromosomal abnormality

Case	Maternal Age	Gestational Age	Antenatal screening	Cardiac finding	Extracardiac finding	Soft marker	Karyotype
1	35	22+2	NP	Subaortic VSD	DWM, single umbilical arter, FGR	None	Trisomy 21
2	28	23+4	Positive (FTS), cffDNA	AVSD	None	Nasal bone hypoplasia	Trisomy 21
3	33	21+5	Positive (QT)	None	Omphalocele,	None	Trisomy 21
4	27	22+0	NP	None	Bilateral clubfoot	Mild pyelectasis	Trisomy 21
5	36	32+1	NP	Coarctation of aorta PLSVC	None	Short femur	Trisomy 21
6	25	21+2	Negative (TT)	Inlet VSD	None	EIF	Trisomy 21
7	32	23+3	Positive (FTS)	None	Ventriculomegaly, PRUV	Nasal bone hypoplasia	Trisomy 21
8	38	19+2	Positive (FTS), cffDNA	Tetralogy of fallot	None	Thick nuchal fold	Trisomy 21
9	36	24+1	NP	None	Ventriculomegaly	EIF	Trisomy 21
10	30	15+5	Positive (FTS)	None	Cystic hygroma	None	Trisomy 21
11	40	18+3	Negative (TT)	Inlet VSD	None	None	Trisomy 21
12	27	22+4	Negative (FTS)	None	FGR	EIF	Trisomy 21
13	41	21+1	Negative (QT)	None	None	EIF, HEB	Trisomy 21
14	28	20+3	Positive (cffDNA)	None	None	Mild pyelectasis	Trisomy 21

15	35	21+2	NP	None	None	None	None	Trisomy 21
16	29	23+4	Negative(TT)	None	None	None	None	Trisomy 21
17	36	22+4	Negative (QT)	DORV	Thymic hypoplasia	None	None	22q11.2 del
18	27	24+0	Negative (FTS,TT)	None	None	None	None	22q11.2 del
19	38	20+5	NP	None	None	None	None	22q11.2 del
20	26	22+1	Negative (QT)	None	None	None	None	45,X0
21	29	23+0	Positive(FTS)	None	None	None	None	45,X0
22	24	22+4	NP	None	ACC, ventriculomegaly, hand/foot deformities	Nasal bone hypoplasia	None	Trisomy 18
23	30	19+5	Positive (FTS)	None	Micrognathia, hand/foot deformities	HEB	None	Trisomy 18
24	33	20+1	NP	AVSD	FGR, single umbilical artery,	None	None	Trisomy 18
25	31	18+5	Positive (FTS)	DORV	Polihidramnios, FGR	HEB	None	Trisomy 18

NP: Not performed, DORV: Double outlet right ventricle, VSD: Ventricular septal defect, AVSD: Atrioventricular septal defect, PLSVC: Persistent left superior vena cava, EIF: Echogenic intracardiac focus, DWM: Dandy Walker malformation, FGR: Fetal growth restriction, HEB: Hyperechoic bowel, ACC: Agenesis of corpus callosum, FTS: First trimester screening, TT: Triple test, QT: Quadruple test, cffDNA: Cell free fetal DNA, ARSA: Aberrant right subclavian artery

Although the relationship between ARSA and Down syndrome has been demonstrated, there are conflicting data in the literature regarding the association of isolated ARSA and trisomy 21 or other chromosomal abnormalities to recommend karyotyping⁽²⁰⁾. Rembouskos et al.⁽²¹⁾ detected DiGeorge syndrome in a case of ARSA with only increased NT as an additional finding and emphasized the addition of FISH analysis for microdeletion syndromes to fetal karyotyping, even if ARSA was the only ultrasound finding on the second or third trimester.

We detected three cases with 22q11 deletion and in two of them, ARSA was the only ultrasound finding in the second-trimester fetal anatomic survey and one case with DORV and thymic hypoplasia.

Aortic arch abnormalities can be observed in Turner syndrome. However, there are limited data in the literature about the relationship between Turner syndrome and ARSA. In a study with 99 patients with Turner syndrome, ARSA was reported in 8% of cases⁽²²⁾.

ARSA was the only ultrasound finding in the second-trimester fetal anatomic screening in two fetuses in which we found Turner syndrome. Antenatal screening tests were not performed in one of the cases, but the other had increased nuchal translucency at the first-trimester screening.

Conclusion

ARSA may be the only ultrasound finding in trisomy 21 and also in DiGeorge and Turner syndrome in the second or third trimester. Hence, imaging the right subclavian artery should be part of the fetal anatomical survey and standard karyotyping and

FISH analysis should be recommended, even in isolated ARSA, especially in patients who do not have antenatal screening tests.

Ethics

Ethics Committee Approval: This study was approved by our institutional review board (approved number: KAEK/2019.03.46).

Informed Consent: A waiver of informed consent was obtained owing to the study's retrospective nature.

Peer-review: Externally peer-reviewed.

Authorship Contributions

Surgical and Medical Practices: M.B., S.S.Ç., S.S., A.Ç.E., Concept: M.B., S.S.Ç., S.C.O., S.S., A.Ç.E., Design: M.B., S.S.Ç., S.C.O., S.S., A.Ç.E., Data Collection or Processing: M.B., S.S.Ç., S.S., A.Ç.E., Analysis or Interpretation: M.B., S.S.Ç., S.C.O., Literature Search: M.B., S.S.Ç., S.C.O., Writing: M.B., S.S.Ç., S.C.O., Critical Review: M.B., S.S.Ç., S.C.O.

Conflict of Interest: The authors report no conflict of interest.

Financial Disclosure: Authors have no financial interests about the research.

References

1. Zapata H, Edwards JE, Titus JL. Aberrant right subclavian artery with left aortic arch: associated cardiac anomalies. *Pediatr Cardiol* 1993;14:159-61.
2. Scala C, Leone Roberti Maggiore U, Candiani M, Venturini PL, Ferrero S, Greco T, et al. Aberrant right subclavian artery in fetuses with Down syndrome: a systematic review and meta-analysis. *Ultrasound Obstet Gynecol* 2015;46:266-76.
3. Borenstein M, Minekawa R, Zidere V, Nicolaidis KH, Allan LD. Aberrant right subclavian artery at 16 to 23 + 6 weeks of gestation:

- a marker for chromosomal abnormality. *Ultrasound Obstet Gynecol* 2010;36:548-52.
4. Quarello E, Carvalho JS. Prenatal diagnosis of an aberrant right subclavian artery: four vessels arising from the aortic arch? *Ultrasound Obstet Gynecol* 2009;33:492-3; author reply 493-4.
 5. Esmer AC, Gul A, Nehir A, Yuksel A, Dural O, Kalelioglu I, et al. Detection rate of trisomy 21 in fetuses with isolated and non-isolated aberrant right subclavian artery. *Fetal Diagn Ther* 2013;34:140-5.
 6. Polguy M, Chrzanowski Ł, Kasprzak JD, Stefańczyk L, Topol M, Majos A. The aberrant right subclavian artery (arteria lusoria): the morphological and clinical aspects of one of the most important variations--a systematic study of 141 reports. *ScientificWorldJournal* 2014;2014:292734. doi: 10.1155/2014/292734.
 7. Chaoui R, Heling KS, Sarioglu N, Schwabe M, Dankof A, Bollmann R. Aberrant right subclavian artery as a new cardiac sign in second- and third-trimester fetuses with Down syndrome. *Am J Obstet Gynecol* 2005;192:257-63.
 8. De León-Luis J, Bravo C, Gámez F, Ortiz-Quintana L. Coronal view as a complementary ultrasound approach for prenatal diagnosis of aberrant right subclavian artery. *Ultrasound Obstet Gynecol* 2012;40:370-1.
 9. Gul A, Corbacioglu A, Bakirci IT, Ceylan Y. Associated anomalies and outcome of fetal aberrant right subclavian artery. *Arch Gynecol Obstet* 2012;285:27-30.
 10. Borenstein M, Cavoretto P, Allan L, Huggon I, Nicolaidis KH. Aberrant right subclavian artery at 11 + 0 to 13 + 6 weeks of gestation in chromosomally normal and abnormal fetuses. *Ultrasound Obstet Gynecol* 2008;31:20-4.
 11. Pico H, Mancini J, Lafouge A, Bault JP, Gorincour G, Quarello E. Prenatal associated features in fetuses diagnosed with an aberrant right subclavian artery. *Fetal Diagn Ther* 2016;40:187-94.
 12. Rauch R, Rauch A, Koch A, Zink S, Kaulitz R, Girisch M, et al. Laterality of the aortic arch and anomalies of the subclavian artery--reliable indicators for 22q11.2 deletion syndromes? *Eur J Pediatr* 2004;163:642-5.
 13. McElhinney DB, Clark BJ 3rd, Weinberg PM, Kenton ML, McDonald-McGinn D, Driscoll DA, et al. Association of chromosome 22q11 deletion with isolated anomalies of aortic arch laterality and branching. *J Am Coll Cardiol* 2001;37:2114-9.
 14. Oğlak SC, Bademkiran MH, Obut M. Predictor variables in the success of slow-release dinoprostone used for cervical ripening in intrauterine growth restriction pregnancies. *J Gynecol Obstet Hum Reprod* 2020;49:101739. doi: 10.1016/j.jogoh.2020.101739.
 15. Karcaaltincaba M, Haliloglu M, Ozkan E, Kocak M, Akıncı D, Anyurek M. Non-invasive imaging of aberrant right subclavian artery pathologies and aberrant right vertebral artery. *British J Radiol* 2009;82:73-8.
 16. Zalel Y, Achiron R, Yagel S, Kivilevitch Z. Fetal aberrant right subclavian artery in normal and Down syndrome fetuses. *Ultrasound Obstet Gynecol* 2008;31:25-9.
 17. Svirsky R, Reches A, Brabbing-Goldstein D, Bar-Shira A, Yaron Y. Association of aberrant right subclavian artery with abnormal karyotype and microarray results. *Prenat Diagn* 2017;37:808-11.
 18. Paladini D, Sglavo G, Pastore G, Masucci A, D'Armiento MR, Nappi C. Aberrant right subclavian artery: incidence and correlation with other markers of Down syndrome in second-trimester fetuses. *Ultrasound Obstet Gynecol* 2012;39:191-5.
 19. Chaoui R, Thiel G, Heling KS. Prevalence of an aberrant right subclavian artery (ARSA) in fetuses with chromosomal aberrations. *Ultrasound Obstet Gynecol* 2006;28:414-5.
 20. Boudjemline Y, Fermont L, Le Bidois J, Lyonnet S, Sidi D, Bonnet D. Prevalence of 22q11 deletion in fetuses with conotruncal cardiac defects: a 6-year prospective study. *J Pediatr* 2001;138:520-4.
 21. Rembouskos G, Passamonti U, De Robertis V, Tempesta A, Campobasso G, Volpe G, et al. Aberrant right subclavian artery (ARSA) in unselected population at first and second trimester ultrasonography. *Prenat Diagn* 2012;32:968-75.
 22. Mortensen KH, Hjerrild BE, Andersen NH, Sørensen KE, Hørlyck A, Pedersen EM, et al. Abnormalities of the major intrathoracic arteries in Turner syndrome as revealed by magnetic resonance imaging. *Cardiol Young* 2010;20:191-200.