



Prenatal diagnosis of pectus excavatum

Pektus ekskavatumun prenatal tanısı

Cihan Çetin, Selim Büyükkurt, Mete Sucu, Mehmet Özsürmeli, Cansun Demir

Çukurova University Faculty of Medicine, Department of Obstetrics and Gynecology, Adana, Turkey

Abstract

Pectus excavatum (PE) is the depression of the lower part of manubrium sterni and xiphoid process. The main problem of PE depends on the cardiopulmonary morbidity caused by the narrowing of the thoracic space. To date, prenatal diagnosis of this deformity has been reported only once and was associated with Down syndrome. We present another case which we diagnosed as PE during a second-trimester fetal anatomic scan. The pectus severity index is used for these patients in postnatal life; however, prenatal adaption of this index is reported for the first time in our case.

Keywords: Funnel chest, prenatal diagnosis, ultrasonography, prenatal

Öz

Pektus ekskavatum (PE) manubrium sterninin alt kısmının ve ksifoid çıkıntının içe doğru çöküntüsü olarak tanımlanır. PE'li hastaların esas problemi torasik boşluğun daralmasına bağlı gelişen kardiyopulmoner morbiditedir. Günümüze kadar bu deformitenin prenatal tanısı sadece bir kez ve Down sendromu ile ilişkili olarak bildirilmiştir. Biz, ikinci trimester fetal anatomik tarama sırasında tespit ettiğimiz bir diğer olguyu sunuyoruz. Pektus şiddeti indeksi, bu hastalar için postnatal dönemde kullanılan bir indekstir; fakat bunun prenatal döneme uyarlanması ilk kez bizim olgumuzda gerçekleştirildi.

Anahtar Kelimeler: Çukur göğüs, prenatal tanı, ultrasonografi, prenatal

Introduction

Pectus excavatum (PE) is the depression of the lower part of manubrium sterni and xiphoid process. It is the most common anterior chest wall deformity. Its incidence is 1 in 400 to 1.000 live births and it is three to five times more common in males⁽¹⁾. PE is usually sporadic but can also be associated with connective tissue disorders, such as Marfan syndrome and Ehlers-Danlos syndrome, neuromuscular disease, and a variety of other genetic conditions, including Noonan syndrome and Turner syndrome.

The main problem of PE depends on the cardiopulmonary morbidity caused by the narrowing of the thoracic space. The severity of the chest wall deformity determines the morbidity. Another problem with PE is the psychosocial problems caused by the cosmetic concerns.

One third of PE patients present during infancy⁽²⁾. Spontaneous regression is rare and progression may continue until the end of adolescence⁽³⁾. The main symptoms of these patients are exertional intolerance, chest pain, and shortness of breath. Respiratory problems may even begin during infancy.

Until now, prenatal diagnosis of this deformity has been reported only once by Salamanca et al.⁽⁴⁾ in two patients who

postnatally diagnosed as having Down syndrome. In this report, we present another case which we diagnosed as PE during a second-trimester fetal anatomic scan.

Case Report

A pregnant woman aged 35 years presented during her 23rd week of gestation for a routine fetal anatomic scan. Her medical history was not significant for any clinical condition. She had a healthy boy aged 11 years delivered by cesarean section. The ultrasound examination was performed using a Voluson 730 Pro with RAB2-5L 3D abdominal transducer (2-5 MHz) probe. Fetal biometric measures were compatible with the gestational age. The fetus had a normal anatomic scan except for the depression at the lower part of the sternum. The depression at this level was seen in both the transverse and sagittal sections of the lower thorax (Figure 1). The defect did not deteriorate the cardiac functions of the fetus. Pectus severity index (PSI) as adopted from postnatal method was calculated as 1.44 (Figure 1). There was no family history for any anterior chest wall deformity. The patient delivered a 3.100 g male baby during the 39th week of gestation by cesarean section with an Apgar score of 9/10. Postnatal examination confirmed the diagnosis of PE and he

Address for Correspondence/Yazışma Adresi: Cihan Çetin, MD,

Çukurova University Faculty of Medicine, Department of Obstetrics and Gynecology, Adana, Turkey

Phone: +90 533 224 10 33 E-mail: cihancetin00@gmail.com

Received/Geliş Tarihi: 13.01.2016 Accepted/Kabul Tarihi: 07.04.2016

©Turkish Journal of Obstetrics and Gynecology, Published by Galenos Publishing House.

This article is distributed under the terms of the "Creative Commons Attribution NonCommercial 4.0 International Licence (CC BY-NC 4.0)".

had no cardiopulmonary complications during the two-year follow-up period (Figure 2). The child was otherwise healthy. Therefore, surgical correction of the deformity was postponed until after the end of adolescence.

Discussion

PE is an anterior chest wall deformity that primarily compromises cardiopulmonary functions in severe cases. However, cosmetic problems are the major problem for most patients. Currently, surgery is the only treatment approach for these patients. Severe chest wall restriction could initiate symptoms during infancy and may require surgical treatment during this period. For other patients, surgery is usually postponed until the end of adolescence, because the deformity may worsen during the growth spurt of adolescence.

Severity of PE is defined by PSI, which is measured using a computerized tomography scan of the thorax⁽⁵⁾. PSI is the ratio of the lateral diameter of the chest to the distance between the sternum and spine at the point of maximal depression⁽⁵⁾.

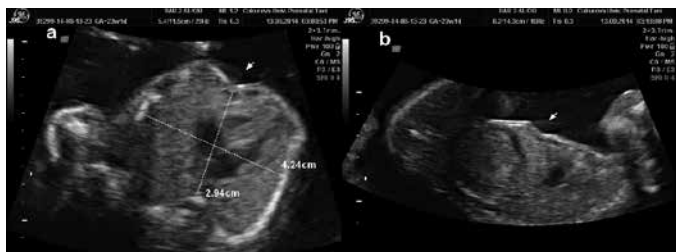


Figure 1. Ultrasonographic images of pectus excavatum, a) Axial thoracic section, pectus severity index is calculated by the ratio of the lateral diameter of the chest to the distance between the sternum and spine at the point of maximal depression (pectus severity index: 4.24 cm/2.94 cm=1.44), b) Sagittal thoracic section (arrows indicate the defect)

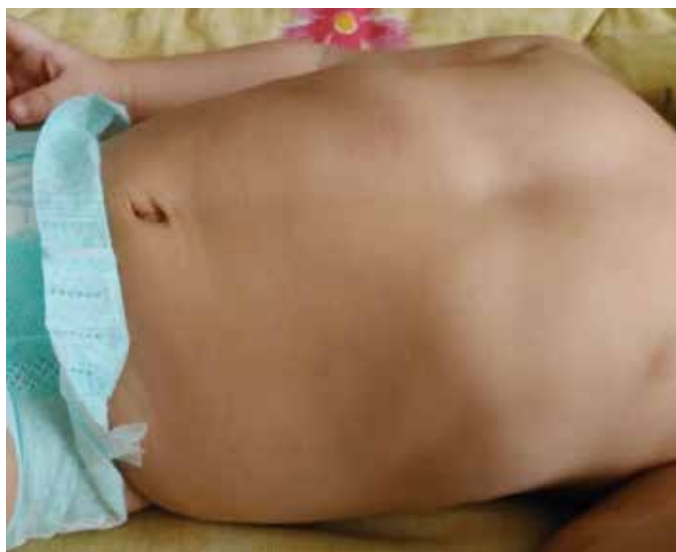

Figure 2. Postnatal photograph of the child with pectus excavatum

Surgery is offered to patients with a PSI of >3.25 ⁽⁵⁾. Prenatal adaptation of this index is reported for the first time in our case. The PSI of our fetus (1.44) was consistent with good prognosis (PSI <3.25), which can be defined as deferability of surgery at least until the end of adolescence. Other tests needed for these patients are electrocardiography, echocardiography, and exercise tests in order to establish preoperative cardiopulmonary functions.

To the best of our knowledge, prenatal diagnosis of PE has been reported only once in the literature, in 1992⁽⁴⁾. In that report, two cases were described and both were later diagnosed as having Down syndrome, even though children with Down syndrome rarely have PE. In our case, PE was not associated with any genetic syndrome like Down, Turner or Noonan. Routine karyotyping may not be necessary for prenatally-diagnosed cases. Congenital cardiac anomalies (atrial/ventricular septal defects, partial atrioventricular septal defects), cardiac malpositioning or pericardial effusion are associated with PE⁽⁶⁾. Therefore, these fetuses should be examined thoroughly for any cardiac anomaly.

Consequently, chest wall examination should be incorporated into the routine fetal anatomic scan during the second trimester. Accompanying abnormal findings may require karyotyping. Patients should be counseled that this is rarely associated with genetic syndromes and prognosis depends mainly on the severity of the defect and cardiopulmonary complications it causes. PSI might be a promising marker for determining the prognosis of such fetuses if it can be supported by other studies.

Ethics

Informed Consent: It was taken from the patient.

Peer-review: Externally peer-reviewed.

Authorship Contributions

Surgical and Medical Practices: Cihan Çetin, *Concept:* Cihan Çetin, Selim Büyükkurt, Cansun Demir, *Design:* Cihan Çetin, Mete Sucu, Mehmet Özsürmeli, Cansun Demir, *Data Collection or Processing:* Cihan Çetin, *Analysis or Interpretation:* Cihan Çetin, Selim Büyükkurt, Mete Sucu, *Literature Search:* Cihan Çetin, Mete Sucu, Mehmet Özsürmeli, Cansun Demir, *Writing:* Cihan Çetin, Selim Büyükkurt, Mehmet Özsürmeli.

Conflict of Interest: No conflict of interest was declared by the authors.

Financial Disclosure: The authors declared that this study received no financial support.

References

1. Fokin AA, Steuerwald NM, Ahrens WA, Allen KE. Anatomical, histologic, and genetic characteristics of congenital chest wall deformities. *Semin Thorac Cardiovasc Surg* 2009;21:44-57.
2. Kelly RE, Jr. Pectus excavatum: historical background, clinical picture, preoperative evaluation and criteria for operation. *Semin Pediatr Surg* 2008;17:181-93.

3. Fonkalsrud EW. 912 open pectus excavatum repairs: changing trends, lessons learned: one surgeon's experience. *World J Surg* 2009;33:180-90.
4. Salamanca A, Girona A, Padilla MC, Sabatel RM, Gonzales-Gomez F. Prenatal diagnosis of pectus excavatum and its relation to Down's syndrome. *Ultrasound Obstet Gynecol* 1992;2:446-7.
5. Haller JA, Jr., Kramer SS, Lietman SA. Use of CT scans in selection of patients for pectus excavatum surgery: a preliminary report. *J Pediatr Surg* 1987;22:904-6.
6. Oezcan S, Attenhofer Jost CH, Pfyffer M, Kellenberger C, Jenni R, Binggeli C, et al. Pectus excavatum: echocardiography and cardiac MRI reveal frequent pericardial effusion and right-sided heart anomalies. *Eur Heart J Cardiovasc Imaging* 2012;13:673-9.